

ULRR

Fluoroquinolone-induced achilles tendinopathy – A case report and management recommendations

Item Type	Article
Authors	Feeney, Kaylem M.
Citation	The Foot and Ankle Online Journal;13(4), 12
Publisher	International Foot and Ankle Foundation
Download date	2026-03-07 06:33:35
Item License	https://creativecommons.org/licenses/by-nc-sa/1.0/
Link to Item	https://hdl.handle.net/10344/9731

Fluoroquinolone-induced Achilles tendinopathy – A case report and management recommendations

by Kaylem M. Feeney^{1,2} BSc (Hons), MSc, MChSI

The Foot and Ankle Online Journal 13 (4): 12

Fluoroquinolone antibiotics are frequently used in the management of infection despite being associated with several side effects including the potential to cause tendon injury. While numerous case reports of Achilles tendon injury related to fluoroquinolone exposure exist in the literature, there is a paucity of research evaluating the effectiveness of treatment interventions for the condition. The author presents a case of chronic bilateral Achilles tendinopathy associated with two separate exposures to ciprofloxacin and its subsequent management with eccentric loading exercises and extracorporeal shockwave therapy (ESWT).

Keywords: Fluoroquinolone, complication, Achilles, tendinopathy, ESWT

This is an Open Access article distributed under the terms of the Creative Commons Attribution License. It permits unrestricted use, distribution, and reproduction in any medium, provided the original work is properly cited. ©The Foot and Ankle Online Journal (www.faoj.org), 2020. All rights reserved.

Fluoroquinolone antibiotics have long been used in the management of infection due to their broad spectrum of activity [1]. While the fluoroquinolone class of antibiotics are generally well-tolerated, they have been associated with complications including tendon injury [2]. There have been several case reports in the literature of fluoroquinolone-induced Achilles tendinopathy though few have reported on the effectiveness of interventions in this population.

Case Report

A 69-year-old male presented to the outpatient clinic with a 7-year history of pain in both Achilles tendons. The patient was generally fit and healthy and was taking no medication at the time of appointment. The patient gave a background history of a sudden onset of bilateral Achilles tendon pain during hospitalization for sepsis. The patient had been prescribed ciprofloxacin as an inpatient and within 24 hours had extreme pain in both Achilles tendons. Treatment with ciprofloxacin was ceased immediately and the patient commenced on an alternative

treatment. Pain in the Achilles tendon decreased significantly over the following 6 months though the patient had a persistent low level pain in both Achilles tendons.

Eight months following the initial onset of Achilles tendon pain, the patient suffered a chest infection. The patient was prescribed ciprofloxacin and approximately 72 hours later had extreme debilitating pain in both Achilles tendons, worse than the initial occasion up to the point where he was unable to walk. Antibiotic therapy with ciprofloxacin was ceased and the patient treated with an alternative antibiotic and the chest infection cleared uneventfully. However, on this occasion, the pain in the Achilles tendons did not improve. The patient was unable to do any significant exercise and had made no significant progress in terms of pain or function over the following 6 years despite rest, stretching, strengthening and physical therapy.

1 - Bon Secours Hospital, Galway, Ireland

2 - School of Medicine, University of Limerick, Ireland

* - Corresponding author: kaylemfeeney1995@gmail.com

Physical examination showed thickening of the midportion of the Achilles tendon bilaterally with pain on palpation and during a single leg heel raise.

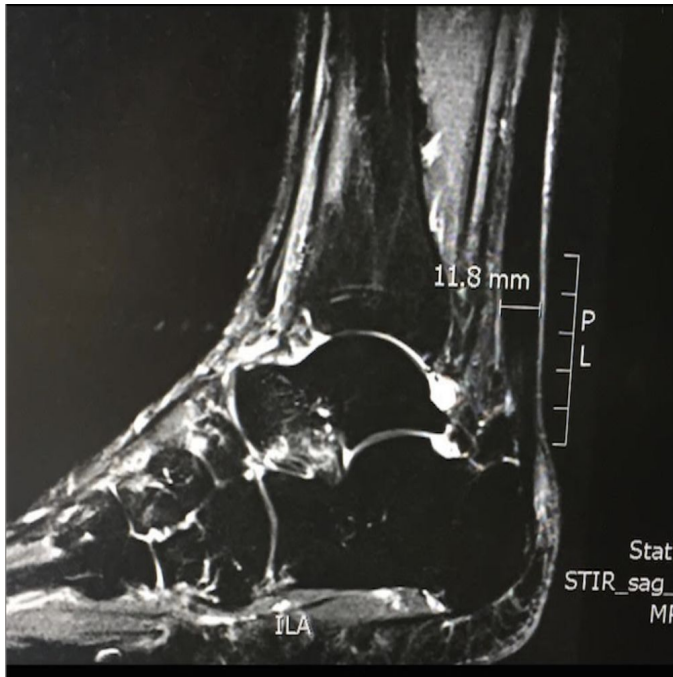

Figure 1 Sagittal view MRI showing Achilles tendon thickness of 11.8mm.

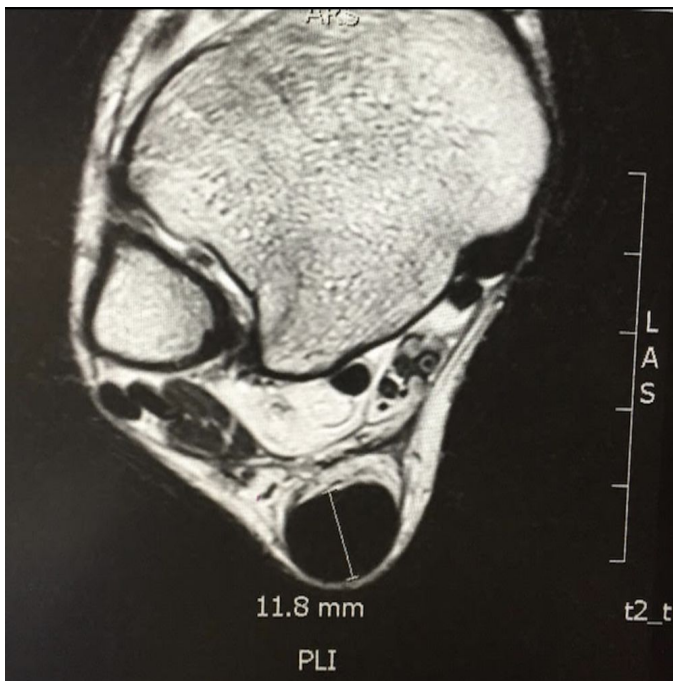


Figure 2 Axial view MRI showing Achilles tendon thickness of 11.8mm.

MRI examination showed gross thickening of the Achilles tendon measuring 11.8mm on the sagittal view (Figure 1) consistent with chronic Achilles tendinosis. Axial view MRI also demonstrated

significant thickening of the Achilles tendon in keeping with chronic Achilles tendinosis (Figure 2).

On the day of presentation the patient had a VAS score of 7/10 on a daily basis and a Roles and Maudsley score of 4.

The patient was commenced on Alfredson’s protocol [3] for Achilles tendinopathy and treated with three sessions of extracorporeal shockwave therapy (ESWT), which has shown to be effective in the management of non-insertional Achilles tendinopathy [4]. ESWT in this case consisted of treatment with 2,500 impulses at a frequency of 10Hz on three occasions spaced one week apart. At the 3-month follow up the patient reported a reduction in pain levels with a VAS score of 3/10. His Roles and Maudsley score had also improved from a score of 4 to a score of 2. At the 6-month follow up, the patient had a VAS score of 2/10 and a Roles and Maudsley score of 2. While the patient still had pain, this pain had improved significantly suggesting that treatment with eccentric loading exercises following Alfredson’s protocol [3] combined with a course of ESWT may be beneficial in reducing pain and improving function in patients with chronic, recalcitrant fluoroquinolone-induced Achilles tendinopathy.

Discussion

Fluoroquinolone antibiotics are becoming increasingly utilized because of their broad antibacterial spectrum and extensive tissue penetration [5]. The most frequently seen adverse effects include headache, skin reaction and gastrointestinal upset [6]. However, fluoroquinolone use has also been linked to tendon injury and tendon rupture including tendinopathy of the biceps brachii, supraspinatus, extensor pollicis longus and Achilles tendons [7]. The first reported case of fluoroquinolone-associated Achilles tendinopathy was in 1983 [5] and since then more than 100 cases have been reported in the literature [8]. The mechanisms of tenotoxic effects of fluoroquinolone antibiotics are unclear, though three main mechanisms have been proposed in the literature and include tendon ischaemia, degradation of tendon matrix and alteration of tenocyte activity [9]. The cause of Achilles tendinopathy not related to fluoroquinolone use is not fully understood but in the absence of acute rupture in trauma it is generally considered an overuse syndrome due to excessive loading of the tendon during activity [6,8,10,11,12]. Management is primarily conservative with rest, non-steroidal anti-inflammatory medication, steroid

injection therapy, stretching, strengthening, prolotherapy, ESWT and platelet-rich plasma injection all being proposed as treatment options in the literature [13,14,15]. Fluoroquinolone-induced Achilles tendinopathy normally resolves within 2 months [15] though prolonged symptoms have been reported in one case lasting two years [15]. The effective management of fluoroquinolone-induced Achilles tendinopathy is not well documented in the literature with the majority of case reports failing to report method of treatment and success rates of treatment [14,15]. Treatment in the literature has focussed on cessation of fluoroquinolone therapy immediately followed by a period of rest and/or immobilisation [15-20]. In this present case, cessation of therapy and subsequent rest was unsuccessful in the improvement of the patient's symptoms and as such further treatment was required. Alfredson's protocol [3] has been shown to be effective in the management of non-insertional Achilles tendinopathy [21,22]. The patient also received three sessions of ESWT, spaced one week apart, with 2,500 impulses at a frequency of 10Hz per treatment. The mechanism of action of ESWT and its effect on tendon tissue is not fully understood though there is research to suggest that ESWT promotes neovascularization and has an inhibitory effect on nociceptors in animal models [23,24]. Furthermore, a review of biological studies has suggested that the mechanical stimulation of tenocytes during ESWT stimulates an increase in the production and release of various growth factors and the proliferation in fibroblasts [25]. However, further biological studies are necessary to fully understand the effects of ESWT on human tendon.

In this case, treatment with Alfredson's protocol [3] combined with a course of ESWT was effective in significantly reducing the patients symptoms over a 3-month period and these improvements were maintained at 6 months. Despite the limitations of a single case study, treatment with a combination of ESWT and eccentric loading following Alfredson's protocol [3] may be considered in cases where cessation of fluoroquinolone therapy and rest/immobilisation fail to resolve a patient's symptoms.

Conclusion

Clinicians should be aware of the risk of fluoroquinolone treatment in the development of Achilles tendinopathy. If Achilles tendinopathy is suspected during therapy, cessation of treatment and rest is important in order to prevent progression of

tendon damage and worsening of symptoms. If the condition fails to improve, eccentric loading following Alfredson's protocol combined with a course of ESWT may improve patient symptoms and allow a return to exercise. Further research with a large sample size and longer follow-up is necessary to confirm these promising results.

References

1. King DE, Malone R, Lilley SH. New Classification and Update on the Quinolone Antibiotic. *Am Fam Physician* 2000;61(9):2741-2748.
2. Stahlmann R, Lode H. Toxicity of Quinolones. *Drugs* 1999; 58(2):37-42.
3. Alfredson H, Pietilä T, Jonsson P, Lorentzon R. Heavy-Load Eccentric Calf Muscle Training For the Treatment of Chronic Achilles Tendinosis. *Am J Sports Med.* 1998;26(3):360-366.
4. Rasmussen S, Christensen M, Mathiesen I, Simonson O. Shockwave Therapy for Chronic Achilles Tendinopathy: A Double-Blind, Randomized Clinical Trial of Efficacy. *Acta Orthop* 2008;79(2):249-256.
5. Bailey RR, Kirk JA, Peddie BA. Norfloxacin Induced Rheumatoid Disease. *N Z Med J* 1983;96(736):590.
6. Yu C, Giuffre BM. Achilles Tendinopathy After Treatment With Fluoroquinolone. *Australasian Radiology* 2005;49(5):407-410.
7. Van Der Linden PD, Van Puijenbroek EP, Feenstra J. Tendon Disorders Attributed to Fluoroquinolones: A Study on 42 Spontaneous Reports in the Period 1988-1998. *Arthritis Care Res* 2001;45(3):235-239.
8. Tam PK, Ho CTK. Fluoroquinolone-Induced Achilles Tendinitis. *Hong Kong Med J* 2014; 20(6):545-547.
9. Childs SG. Pathogenesis of Tendon Rupture Secondary to Fluoroquinolone Therapy. *Orthop Nurs* 2007;26(3):175-182.
10. Kim GK, Del Rosson JQ. The Risk of Fluoroquinolone-Induced Tendinopathy and Tendon Rupture: What Does the Clinician Need to Know? *J Clin Aesthet Dermatol* 2010;3(4):49-54.
11. Mafulli N, Sharma P, Luscombe KL. Achilles tendinopathy: Aetiology and Management. *J R Soc Med* 2004;97(10):472-476.
12. Horn A, McCollum G. Achilles Tendinopathy – Part 1: Aetiology, Diagnosis and Non-Surgical Management. *SA Orthop J* 2015;14(3):24-31.
13. Roche AJ, Calder JDF. Achilles Tendinopathy: A Review of the Current Concepts of Treatment. *J Bone Joint Surg* 2013;95(10):1299-1307.
14. Lewis T, Cook J. Fluoroquinolones and Tendinopathy: A Guide for Athletes and Sports Clinicians and a Systematic Review of the Literature. *J Athl Train* 2014; 49(3):422-427.
15. Khaliq Y, Zhanel GG. Fluoroquinolone-Associated Tendinopathy: A Critical Review of the Literature. *Clin Infect Dis* 2003;36(11):1404-1410.
16. Zabraniecki L, Negrier I, Vergne P, Arnaud M, Bonnet C, Bertin P, Treves R. Fluoroquinolone Induced Tendinopathy: Report of 6 Cases. *J Rheumatol*, 1996;23(3):516-520.

17. Ribard P, Audisio F, Kahn MF, De Bandt M, Jorgensen C, Hayem G, Meyer O, Palazzo E. Seven Achilles Tendinitis Including 3 Complicated by Rupture During Fluroquinolone Therapy. *J Rheumatol* 1992;19(9):1479-1481.
18. Meyboom RHB, Olsson S, Knol A, Dekens-Konter JAM, De Koning GHP. Achilles Tendinitis Induced by Pefloxacin and other Fluoroquinolone Derivatives. *Pharmacoepidemiol Drug Saf* 1994;3:185-189.
19. Carrasco JM, Garcia B, Andujar C, Garrote F, de Juana P, Bermejo T. Tendonitis Associated with Ciprofloxacin. *Ann Pharmacother* 1997;31(1):120.
20. Lewis JR, Gums JG, Dickensheets DL. Levofloxacin-Induced Bilateral Achilles Tendonitis. *Ann Pharmacother* 1999;33(7):792-795.
21. Stevens M, Tan CW. Effectiveness of the Alfredson Protocol Compared with Lower Repetition-Volume Protocol for Midportion Achilles Tendinopathy: A Randomized Controlled Trial. *J Orthop Sports Phys Ther* 2014;44(2):59-67.
22. Van der Plas A, de Jonge S, de Vos RJ, van der Heide HJL, Verhaar JAN, Weir A, Tol JL. A 5-year Follow-Up Study of Alfredson's Heel-Drop Exercise Programme in Chronic Midportion Achilles Tendinopathy. *Br J Sports Med* 2012;46(3):214-218.
23. Wang CJ, Huang HY, Pai CH. Shock Wave Enhances Neovascularization at the Tendon-Bone Junction. *J Foot Ankle Surg* 2002;41(1):16-22.
24. Wang CJ, Wang FS, Yang KD, Huang CS, Hsu CC, Yang LC. Shock Wave Therapy Induced Neovascularization at the tendon-Bone Junction: A Study in Rabbits. *J Orthop Res* 2003;21(6):984-989.
25. Notarnicola A, Moretti B. The Biological Effects of Extracorporeal Shock Wave Therapy (ESWT) on Tendon Tissue. *Muscles Ligaments Tendons J* 2012;2(1):33-37.